



# Benign paroxysmal positional vertigo in Meniere's disease: systematic review and meta-analysis of frequency and clinical characteristics

Mansur A. Kutlubaev<sup>1,2</sup> · Ying Xu<sup>3,4</sup> · Jeremy Hornibrook<sup>5</sup>

Received: 16 July 2019 / Revised: 5 August 2019 / Accepted: 7 August 2019 / Published online: 13 August 2019  
© Springer-Verlag GmbH Germany, part of Springer Nature 2019

## Abstract

There is a recognized association of Meniere's disease (MD) and benign paroxysmal positional vertigo (BPPV). However, the frequency and clinical characteristics of BPPV in MD are unclear. The aim of this review was to determine the mean frequency and clinical features of BPPV in MD. Three databases were searched: MEDLINE, PubMed and Google Academia. Studies reporting the frequency of BPPV in MD were pooled. A total of 4198 references were identified, of which 20 studies were considered eligible. The pooled frequency of BPPV in MD was 14% (95% CI 9–18%). It was 38% (95% CI 26–49%) in longitudinal studies and 8% (95% CI 6–11%) in cross-sectional ones. BPPV comorbid with MD was mostly observed in the ear affected by hydrops, in females, in patients with more advanced disease. Canalolithiasis of the horizontal semicircular canal was more common in patients with BPPV associated with MD than in idiopathic BPPV. BPPV in MD was more prone to recurrence and required more canal repositioning maneuvers.

**Keywords** Benign paroxysmal positional vertigo · Meniere's disease · Hydrops · Otolithiasis · Vertigo

## Introduction

Benign paroxysmal positional vertigo (BPPV) is the most common cause of vertigo in clinical practice. It develops because of degeneration of the utricular neuroepithelium leading to the detachment of otoconia, which freely float in semicircular canals (SCCs), or attach to the cupula, making the labyrinth sensitive to gravitational forces [1]. Most BPPV cases are idiopathic; however, some are secondary.

The latter develop in inner ear diseases, after vestibular neuritis or head trauma [1, 2].

Meniere's disease (MD) is a chronic progressive multifactorial condition presenting with recurrent vertigo attacks, fluctuating hearing loss, tinnitus and aural fullness [3]. The basic pathophysiological feature of MD is excessive endolymph in the endolymphatic space, called endolymphatic hydrops. The cause of the hydrops is unknown. The main theories are a viral infection, autoimmune involvement of the sac, a genetically determined abnormality of endolymph control, and variations in the size and position of the sac and endolymphatic duct [4].

According to Schuknecht's histopathological studies [5], vertiginous attacks in MD develop as a result of the rupture of Reissner's membrane and potassium intoxication of the perilymph. Contemporary studies do not support this theory [6].

The drainage theory by Gibson and Arenberg attempts to explain the attacks by a dysfunctional or blocked endolymphatic sac, which impairs longitudinal flow of endolymph, leading to its buildup in the sinus of the endolymphatic duct. Excessive endolymph refluxes through the utricular valve of Bast and into the ampullae of the semicircular canals and results in the attack of vertigo [6].

✉ Mansur A. Kutlubaev  
Mansur.Kutlubaev@yahoo.com

<sup>1</sup> Department of Neurology, Bashkir State Medical University, Ufa, Russia

<sup>2</sup> Department of Neurology, G.G. Kuvatov Republican Clinical Hospital, Ufa, Russia

<sup>3</sup> Sydney Medical School, University of Sydney, Sydney, NSW, Australia

<sup>4</sup> The George Institute for Global Health, Faculty of Medicine, University of New South Wales, Camperdown, NSW, Australia

<sup>5</sup> Department of Otolaryngology-Head and Neck Surgery and Audiology, Christchurch Hospital, Riccarton Avenue, Christchurch, New Zealand

Recently, it was hypothesized that detached saccular otoconia may be a causative factor for hydrops. There is radiological evidence that detached saccular otoconia may cause obstruction of the reuniting duct leading to endolymphatic hydrops [7]. The combination of the otoconia theory with the drainage theory could explain the pathophysiology of MD [8, 9].

There is a recognized association of Meniere's disease and BPPV [10, 11]. The spectrum of onset age for BPPV and Meniere's disease are so similar that it raises the question of a possible role of otoconia in the development and progression of MD [8, 9].

The true frequency of BPPV in MD is unclear. It varies from 0.3 to 70% according to different studies [12, 13]. It is also unclear whether clinical characteristics of BPPV in MD differ from idiopathic ones. The aim of this review: to determine the frequency and clinical features of BPPV in MD.

## Methods

The systematic review was undertaken following MOOSE guidelines for meta-analysis of observational studies and reported following the PRISMA guidelines [14, 15].

### Search strategy, screening and data extraction

Three databases were searched: MEDLINE, PubMed and Google Academia (from inception to Nov 2018). The following search terms were used as free text or controlled vocabulary (i.e., medical subject headings, Emtree) as appropriate for each database: 'Meniere's disease' AND 'hydrops', 'bppv', 'benign paroxysmal positional vertigo', 'otolithiasis', 'canalolithiasis', 'cupulolithiasis', 'otoconia'. Titles and abstracts of all references were screened and full text articles were examined by one author (MK) to determine whether they met the inclusion criteria. Further literature was sought through the reference lists of eligible studies (MK). Data extraction was conducted by one researcher (MK) and included region/country, recruitment site, study period, age, sample size, frequency of BPPV in MD, method of diagnosis, correlates and outcomes. We included all published observational studies reporting the frequency or characteristics of BPPV in MD, with detailed methodology for diagnosis (i.e., diagnostic guidelines or specified tests). All observational study designs were accepted with the exception of case report and case series of fewer than ten participants.

### Statistical analysis

Studies reporting the frequency of BPPV in MD were pooled. We conducted quantitative synthesis and produced

forest plots in Stata 13 using random effects analysis. Subgroup analysis was conducted based on study design (i.e. longitudinal versus cross-sectional). Statistical heterogeneity and consistency were assessed using the standard  $Q$  statistic, with  $p < 0.05$  and  $I^2$ .

## Results

A total of 4198 references were identified, of which 59 full text articles were retrieved to assess for inclusion/exclusion criteria. A total of 20 studies met our criteria and were considered eligible [11, 16–34] (Fig. 1). Included papers contained data obtained from 3223 people.

All 20 studies were hospital based, and 18 of them had consecutive recruitment. Fourteen studies were retrospective. The frequency of BPPV in MD was reported in 12 studies, whilst only the clinical characteristics of BPPV in MD were reported in the rest of the 8 studies.

MD was diagnosed using guidelines of the American Academy of Otolaryngology-Head and Neck Surgery (AAO-HNS) [35] in 16 studies. Patients underwent Dix–Hallpike maneuver and the supine roll test for the detection of BPPV. Video- or electronystagmography was used in 10 studies.

### Frequency of BPPV in MD

Frequency of BPPV in MD varied from 3.2 to 44% [30, 31]. Two studies reporting frequencies of 75–80% [12] and 0.3% [13] were excluded, because methods were unclear in the former, whilst only patients with BPPV in the ear affected by MD were calculated in the latter. The pooled frequency of BPPV in MD was 14% (95% CI 9–18%) (Fig. 2). In subgroup analysis, the frequency of BPPV in MD was 38% (95% CI 26–49%) in longitudinal studies where MD patients were examined more than once, and was higher than in cross-sectional studies, where it was 8% (95% CI 6–11%).

### Demographic features of patients with BPPV and MD

The majority of patients with comorbid BPPV and MD were females: 78.6% [26], 86.7% [25], 88 [28], 91.6% [27], and 93% [11]. Female preponderance in the BPPV and MD group in comparison to pure BPPV group was reported in two studies [11, 28], but it was not supported by one study [31]. Patients with BPPV and MD were older than those with MD alone [31].

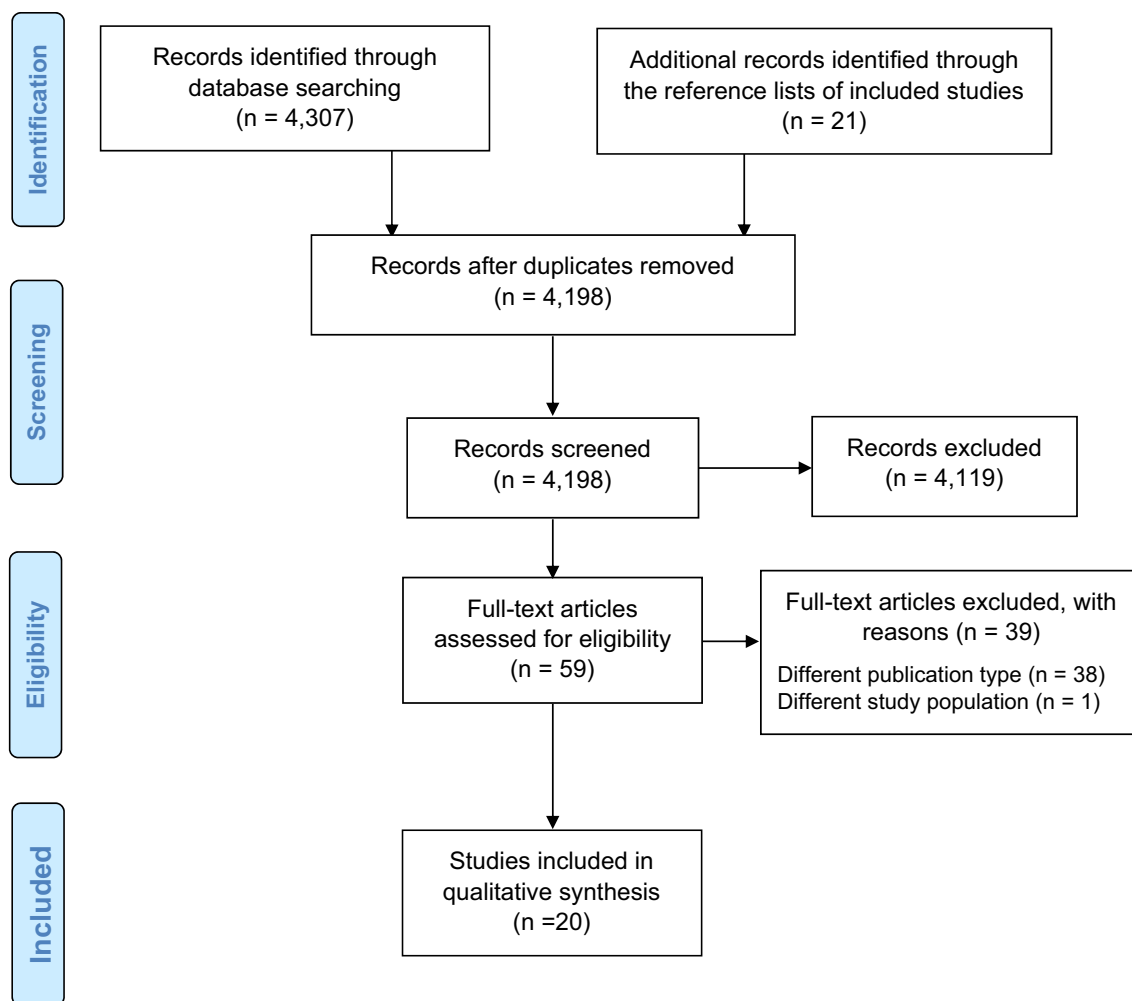


Fig. 1 PRISMA flow diagram for the systematic review process

### Side and semicircular canal affected by BPPV in MD

BPPV developed in the ear with hydrops in 60–100% of MD, unilateral at the time of study (Table 1). In patients with comorbidity, BPPV was more likely to involve the horizontal SCC [11, 26]. BPPV involving multiple SCCs was more [26] or less [11] common in patients with MD (Table 1). Canal paresis reflecting inner ear permanent damage was more common in the BPPV and MD group in comparison to pure BPPV according to 3 works [11, 26, 32].

### Development of BPPV in relation to MD

Three studies ( $n=84$ ) showed that in over 90% of cases, BPPV developed after MD, and one study ( $n=9$ ) reported that all patients developed BPPV before MD (Table 2).

In one study, 89.7% of cases of BPPV developed at the stages 2–3 of MD, and only 10.3% of cases of BPPV were identified at stage 1 of MD [11]. Another study showed that

93.3% of patients with MD and BPPV had stage 2–3 hearing loss, and significantly fewer patients with comorbidity had stage 1 hearing loss in comparison to those with pure MD [25]. Patients with MD and BPPV suffered longer from MD than those without BPPV (25.8 vs 13.2 months respectively,  $p=0.02$ ) according to one study [21].

### Response to repositioning maneuvers and relapse rate of BPPV in MD

Response to repositioning maneuvers in patients with BPPV and MD varied greatly according to the different studies. Gross et al. [22] reported that all nine recruited patients with comorbidity had intractable BPPV, while the rest reported high overall success rate of treatment: 79.5% [26], 90.9% [29] and 100% [16]. One therapeutic session was successful in 63.36% [29], 64.7% [28], 80.6% [16] and 83.3% [34] of cases of BPPV in MD. Li et al. reported that 10 out of 15 patients (66.7%) with comorbidity recovered from BPPV

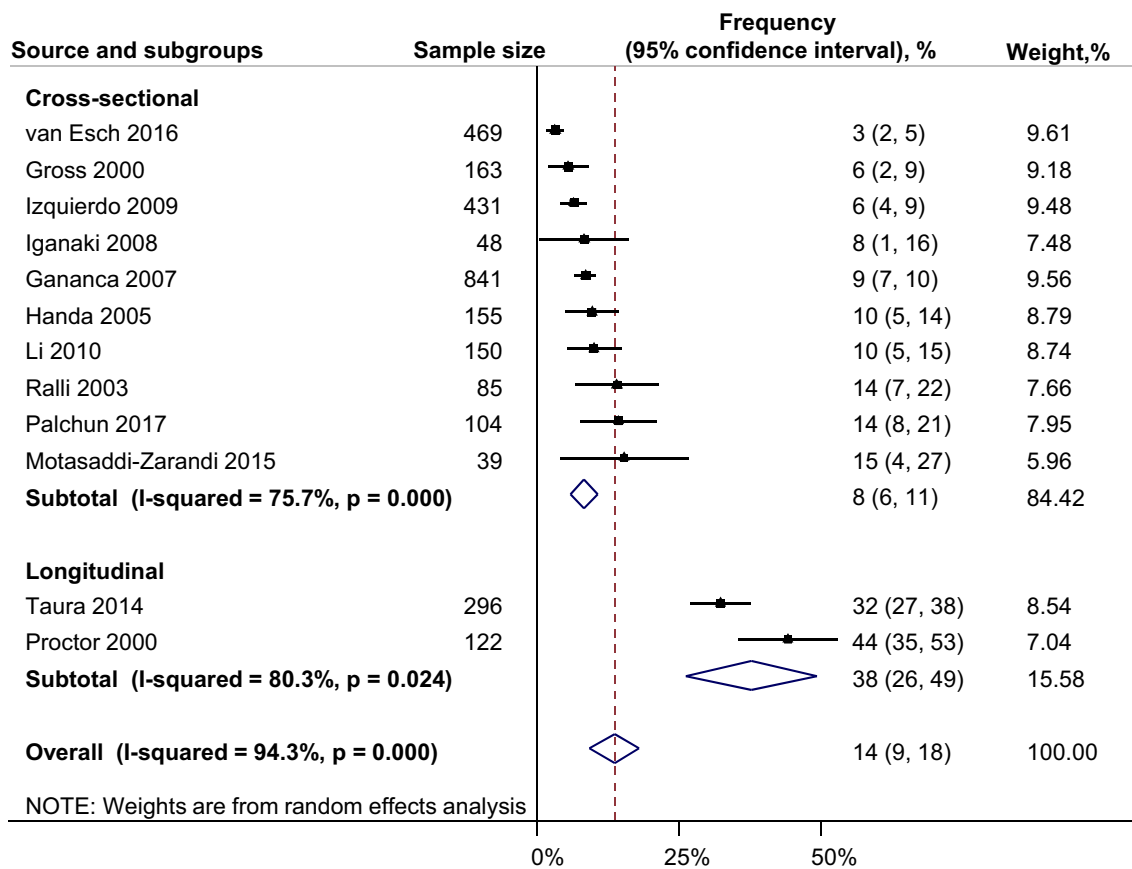


Fig. 2 Frequency of BPPV in MD

Table 1 Involvement of the ear affected by MD and semicircular canals by BPPV in patients with comorbidity

Study	N <sup>a</sup>	Affected ear	Posterior canal BPPV	Horizontal canal BPPV	Anterior canal BPPV
Handa (2005)	15	N/A	12 (80%)	2 (13%)	1 (7%)
Li (2010)	15	13 (87%)	13 (87%)	2 (13%)	–
Taura (2014)	72	49 (68%)	25 (34.7%)	47 (65.3%)	–
Zhu (2018)	13	N/A	8 (61.5%)	5 (38.5%)	–
Yetiser (2007)	17	N/A	8 (47%)	9 (53%)	–
Guo (2015)	36	31 (86%)	22 (61%)	14 (39%)	–
Balatsouras (2012)	29	26 (86.2%)	22 (75.9%)	7 (24.1%)	–
Motasaddi-Zarandi (2015)	6	N/A	6 (100%)	–	–
Ralli (2003)	12	N/A	12 (100%)	–	–
Hugh (1997)	23	16 (69.6%)	N/A	N/A	N/A
Luryi (2018) <sup>b</sup>	112	81 (72.2%)	96 (85.7%)	13 (11.6%)	3 (2.7%)
Zhu (2018)	21	13 (61.5%)	N/A	N/A	N/A
Gananca (2007)	40	39 (97.5%)	N/A	N/A	N/A
Proctor (2000)	28	17 (60.6%)	N/A	N/A	N/A
Gross (2000)	7	7 (100%)	N/A	N/A	N/A
Inagaki (2008)	4	N/A	4 (100%)	–	–

<sup>a</sup>Cases of bilateral MD were excluded

<sup>b</sup>8 (7.1%)—multicanal BPPV

**Table 2** The temporal relationship between the development of BPPV and MD

Study	N	Before MD	Concurrently	After MD	Undetermined
Hughes (1997)	45	1 (2.2%)	–	15 (33.3%)	29 (64.5%)
Gross (2000)	9	9 (100%)	–	–	–
Ganancia (2007)	62	1 (1.5%)	4 (6.5%)	57 (92%)	–
Rossi Izquierdo (2009)	22	2 (9%)	–	20 (91%)	–
Motasaddi-Zarandi (2015)	6	–	–	6 (100%)	–

after 3–4 therapeutic sessions, 4 (26.7%) after at least 5 sessions and 1 (6.6%) required surgical treatment [24]. Patients with BPPV and MD required more canal repositioning maneuvers than those with pure BPPV in one study [11], while in another one there was no difference between two groups [32].

BPPV in patients with MD was more prone to relapse in comparison to idiopathic BPPV [11, 32]. The recurrence rate of BPPV in MD patients was 19.2% [16], 44.4% [11] and 50% [33, 34].

## Discussion

### Causal relationship between otolithiasis and hydrops

Pooled average frequency of BPPV in MD was 14% and was 2.5 times higher in longitudinal studies when MD patients were examined more than once.

The causal relationship between BPPV and MD was suggested by the higher prevalence of otolithiasis in the hydropic ear according to our systematic review. However, otolithiasis in the unaffected ear could be explained by several factors. For instance, people with unilateral hearing loss due to MD may prefer to sleep on the side of the affected ear and make the unaffected ear vulnerable to developing BPPV.

The high prevalence of BPPV in MD could be explained by utricle damage caused by hydrops and subsequent otoclonia detachment [36]. Distension of the membranous labyrinth due to hydrops may also lead to the loss of its resilience, otolith detachment and its partial obstruction. Enlargement of the vestibular aqueduct may also contribute to the development of BPPV in MD [37].

Some authors suggested that both BPPV and MD can be associated with the presence of free-floating particles within the vestibular fluid chambers [38]. Jahn proposed that cellular and proteinaceous components may generate colloidal osmoactivity and lead to hydrops, while the calcified elements may cause gravitational forces and lead to BPPV. In some patients, endolymphatic debris may have both features leading to comorbid BPPV and MD [39]. Otolithiasis could

lead to the development of MD, by causing hydrops through obstructing reuniting ducts [8, 9]. Although in the studies with a relatively large number of participants [16, 19], BPPV developed after the symptoms of MD, only in 1.5–2% of cases BPPV was diagnosed before MD. However, the latter figures could be underestimated, as some cases of BPPV are mild, resolve spontaneously and could be missed by health-care professionals.

The association between BPPV and MD has been confirmed by histopathologic temporal bone studies reporting significantly higher incidence of cupular or free-floating deposits in SCCs in patients with MD than in controls. It mostly correlated with the duration of the disease and condition of the labyrinth, rather than with the age, proving the causal relationship between these two conditions [40].

Head trauma and viral infection were also suggested as common causative factors for both otolithiasis and hydrops. Epidemiological studies showed that both conditions are common after head injury (19% for MD and 28% for BPPV) [39]. On the other hand, Gacek reported histological data demonstrating similar degeneration of vestibular ganglion in patients with MD and BPPV, postulating that herpes virus reactivation can lead to the injury of the membranous labyrinth and can be a common cause for both disorders [41]. Some authors reported positive effect of antiviral medications in MD also lending support to this hypothesis [42].

### Clinical and demographic features of BPPV in MD

BPPV mostly developed in females with MD. On one hand, it could be associated with impaired calcium metabolism, which is often seen in perimenopausal females [43]. On the other hand, female preponderance in MD patients could be a result of misdiagnosis of MD with vestibular migraine, as both disorders could be very similar at early stages [44].

BPPV in MD more often affected the horizontal SCC. This predilection of horizontal semicircular canal to the development of otolithiasis in MD does not have a clear explanation. Some authors believe that anatomical factors are responsible. According to Gürkov et al. horizontal SCC is the predominant canal affected in MD [45].



## Response to repositioning maneuvers and relapse rate of BPPV in MD

Poor response to repositioning maneuvers and high level of relapses of BPPV in MD could be explained by several potential mechanisms. Anatomical changes of labyrinth due to hydrops probably are a main reason for intractability of BPPV in MD. Partial obstruction of the posterior SCC by a dilated saccule could lead to adherence of otoliths to the membranous labyrinth [46]. Partial obstruction allows otoliths to move within canals and prevents them from returning to vestibules.

Stricture of the membranous labyrinth resulting from loss of its resilience after repeated distension due to EH may be another cause. The membrane may collapse inward and lead to severe narrowing of the SCC [22].

Some authors suggest that higher proportion of cupulolithiasis in MD could result in higher frequency of canalith repositioning procedure failure in this group of patients. However, clinical and pathological observations do not support this theory. Latency, transience and fatigability of nystagmus observed in the majority of cases are typical for canalolithiasis [47]. Intraoperative and post-mortem studies reporting free-floating particles in inner ear structures also support that canalolithiasis underlies BPPV in MD [5, 46]. Improperly performed repositioning maneuvers may be another factor contributing to the intractability of BPPV in MD, although most of the reports were from specialized neuro-otology units.

The limitation of this meta-analysis is a high degree of heterogeneity between the studies. Most of the studies were cross-sectional, while few longitudinal studies observed patients for relatively short period of time which could lead to underestimation of the frequency of BPPV in MD.

More research is needed in this area. Future studies should elucidate the nature of association between BPPV and MD: whether the former is an etiological factor or a mere complication in relation to the latter. Longitudinal studies of patients with BPPV as well as invention of high-resolution lifetime imaging techniques of the labyrinth may be helpful.

## Conclusion

BPPV is common in patients with MD, especially among females. It develops at any stage of the disease, but more often in advanced stages. BPPV patients comorbid with MD have horizontal SCCs affected more often. The management of patients with comorbid MD and BPPV may require more repositioning maneuvers.

## Compliance with ethical standards

**Conflicts of interest** On behalf of all authors, the corresponding author states that there is no conflict of interest.

## References

- Kim JS, Zee DS (2014) Clinical practice. Benign paroxysmal positional vertigo. *N Engl J Med* 370:1138–1147. <https://doi.org/10.1056/nejmcp1309481>
- Hemenway WG, Lindsay JR (1956) Postural vertigo due to unilateral sudden partial loss of vestibular function. *Ann Otol Rhinol Laryngol* 65:692–706
- Lopez-Escamez JA, Carey J, Chung WH et al (2015) Diagnostic criteria for Meniere's disease. *J Vestib Res* 25:1–7. [https://doi.org/10.1007/978-4-431-68111-3\\_1](https://doi.org/10.1007/978-4-431-68111-3_1)
- Espinosa-Sanchez JM, Lopez-Escamez JA (2016) Menière's disease. *Handb Clin Neurol* 137:257–277. <https://doi.org/10.1016/b978-0-444-63437-5.00019-4>
- Schuknecht HF (1974) Pathology of the ear. Harvard University Press, Cambridge, p 462 (**Philadelphia: Lea and Febiger, 1974:469**)
- Gibson WPR (2019) Meniere's disease. *Adv Otorhinolaryngol* 82:77–86. <https://doi.org/10.1159/000490274>
- Yamane H, Sunami K, Iguchi H, Sakamoto H, Imoto T, Rask-Andersen H (2012) Assessment of Meniere's disease from a radiological aspect—saccular otoconia as a cause for Meniere's disease? *Acta Otolaryngol* 132:1054–1060. <https://doi.org/10.3109/00016489.2012.680980>
- Hornibrook J, Bird P (2017) A new theory for Meniere's disease: detached saccular otoconia. *Otolaryngol Head Neck Surg* 156:350–352. <https://doi.org/10.1177/0194599816675843>
- Hornibrook J (2018) Saccular otoconia as a cause of Ménière's disease: hypothesis based on two theories. *J Laryngol Otol* 132(9):771–774. <https://doi.org/10.1017/s0022215118001366>
- Karlberg M, Hall K, Quickert N, Hinson J, Halmagyi GM (2000) What inner ear diseases cause benign paroxysmal positional vertigo? *Acta Otolaryngol* 120:380–385. <https://doi.org/10.1080/000164800750000603>
- Balatsouras DG, Ganelis P, Aspris A, Economou NC, Moukous A, Koukoutsis G (2012) Benign paroxysmal positional vertigo associated with Meniere's disease: epidemiological, pathophysiological, clinical, and therapeutic aspects. *Ann Otol Rhinol Laryngol* 121:682–688. <https://doi.org/10.1177/000348941212101011>
- Parapella MM (2008) Benign paroxysmal positional vertigo and other vestibular symptoms in Ménière disease. *Ear Nose Throat J* 87(10):562. <https://doi.org/10.1177/014556130808701006>
- Wu ZM, Zhang SZ, Liu XJ, Chen X, Ji F, Chen AT, Yang WY, Han DY (2007) Benign paroxysmal positioning vertigo related to inner ear disorders. *Zhonghua Er Bi Yan Hou Tou Jing Wai Ke Za Zhi* 42(11):821–825. <https://doi.org/10.1159/000095285>
- Stroup DF, Berlin JA, Morton SC, Olkin I, Williamson GD, Rennie D et al (2000) Meta-analysis of observational studies in epidemiology: a proposal for reporting. *JAMA* 283(15):2008–2012. <https://doi.org/10.1001/jama.283.15.2008>
- Moher D, Liberati A, Tetzlaff J, Altman DG, Altman D, Antes G et al (2009) Preferred reporting items for systematic reviews and meta-analyses: the PRISMA statement. *PLoS Med* 6(7):e1000097. <https://doi.org/10.1371/journal.pmed.1000097>
- Gananca CF, Caovilla HH, Gazzola JM, Gananca MM, Gananca FF (2007) Epley's maneuver in benign paroxysmal positional vertigo associated with Meniere's disease. *Braz J Otorhinolaryngol* 73:506–512. [https://doi.org/10.1016/s1808-8694\(15\)30102-6](https://doi.org/10.1016/s1808-8694(15)30102-6)

17. Proctor LR (2000) Results of serial vestibular testing in unilateral Ménière's disease. *Am J Otol* 21(4):552–558
18. Handa PR, Kuhn AM, Cunha F, Schafflein R, Ganança FF (2005) Quality of life in patients with benign paroxysmal positional vertigo and/or Ménière's disease. *Braz J Otorhinolaryngol* 71(6):776–782. [https://doi.org/10.1016/s1808-8694\(15\)31248-9](https://doi.org/10.1016/s1808-8694(15)31248-9)
19. Hughes CA, Proctor L (1997) Benign paroxysmal positional vertigo. *Laryngoscope* 107(5):607–613. <https://doi.org/10.1097/00005537-199705000-00010>
20. Lee NH, Ban JH, Lee KC, Kim SM (2010) Benign paroxysmal positional vertigo secondary to inner ear disease. *Otolaryngol Head Neck Surg* 143(3):413–417. <https://doi.org/10.1016/j.otohns.2010.06.905>
21. Motasaddi-Zarandi M, Nemati Sh, Panahi R, Akbari M (2015) Benign paroxysmal positional vertigo incidence in Meniere's disease: is Meniere's disease a predisposing factor? *Casp J Neurol Sci* 1(1):7–11. <https://doi.org/10.18869/acadpub.cjns.1.1.7>
22. Gross EM, Ress BD, Viirre ES, Nelson JR, Harris JP (2000) Intractable benign paroxysmal positional vertigo in patients with Meniere's disease. *Laryngoscope* 110(4):655–659. <https://doi.org/10.1097/00005537-200004000-00022>
23. Inagaki T, Yukawa K, Ichimura A, Hagiwara A, Ogawa Y, Kitajima N et al (2008) Clinical study of BPPV-like symptom associated with inner ear disease. *Equilib Res* 67:18–23. <https://doi.org/10.3757/jser.67.18>
24. Li P, Zeng XL, Li YQ, Zhang GH, Ye J (2010) The clinical characteristics of the benign paroxysmal positional vertigo associated with Meniere's disease. *Zhonghua Yi Xue Za Zhi* 90(27):1921–1923
25. Pal'chun VT, Mel'nikov OA, Levina YV, Guseva AL (2018) The peculiar features of the clinical course of Meniere's disease associated with benign paroxysmal positional vertigo. *Vestn Otorinolaringol* 83(1):32–35. <https://doi.org/10.17116/otorino201883132-35>
26. Luryi AL, Lawrence J, Bojrab D, LaRouere M, Babu S, Hong R, Zappia J, Sargent E, Chan E, Naumann IC, Schutt CA (2018) Patient, disease, and outcome characteristics of benign paroxysmal positional vertigo with and without Meniere's disease. *Acta Otolaryngol* 138(10):893–897. <https://doi.org/10.1080/00016489.2018.1484566>
27. Guo X, Wang Q, Mei X, Zhang Z, Yang X, He P (2015) Benign paroxysmal positional vertigo associated with Meniere's disease: analysis of 36 cases. *Lin Chung Er Bi Yan Hou Tou Jing Wai Ke Za Zhi* 29(10):925–927
28. Yetişer S (2017) Co-existence of benign paroxysmal positional vertigo and Meniere's syndrome. *J Int Adv Otol* 13(1):65–68. <https://doi.org/10.5152/iao.2016.2906>
29. Rossi Izquierdo M, Soto Varela A, Santos Pérez S, Labella Caballero T (2009) Association between endolymphatic hydrops and benign paroxysmal positional vertigo: coincidence or causality? *Acta Otorrinolaringol Esp* 60(4):234–237. <https://doi.org/10.1016/j.otorri.2009.02.003>
30. van Esch BF, van Benthem PP, van der Zaag-Loonen HJ, Bruinjtjes TD (2016) Two common second causes of dizziness in patients with Ménière's disease. *Otol Neurotol* 37(10):1620–1624. <https://doi.org/10.1097/mao.0000000000001215>
31. Taura A, Funabiki K, Ohgita H, Ogino E, Torii H, Matsunaga M, Ito J (2014) One-third of vertiginous episodes during the follow-up period are caused by benign paroxysmal positional vertigo in patients with Meniere's disease. *Acta Otolaryngol* 134(11):1140–1145. <https://doi.org/10.3109/00016489.2014.936624>
32. Zhu MC, Zhou F, Tan GJ, Wang M, Yu F, Wang HT, Huang LF, Liang ZJ (2016) Clinical analysis of benign paroxysmal positional vertigo associated with Meniere's disease. *Lin Chung Er Bi Yan Hou Tou Jing Wai Ke Za Zhi* 30(20):1615–1619. <https://doi.org/10.13201/j.issn.1001-1781.2016.20.009>
33. Dornhoffer JL, Colvin GB (2000) Benign paroxysmal positional vertigo and canalith repositioning: clinical correlations. *Am J Otol* 21(2):230–233. [https://doi.org/10.1016/s0196-0709\(00\)80014-9](https://doi.org/10.1016/s0196-0709(00)80014-9)
34. Ralli G, Nota G, Lamberti A, Gallo A (2003) La malattia di Ménière e la vertigine parossistica posizionale. *Arq Otorrinolaringol* 7(1):32–37
35. Committee on Hearing and Equilibrium (1995) Committee on Hearing and Equilibrium guidelines for the diagnosis and evaluation of therapy in Meniere's disease. *Otolaryngol Head Neck Surg* 113:181–185. [https://doi.org/10.1016/s0194-5998\(95\)70102-8](https://doi.org/10.1016/s0194-5998(95)70102-8)
36. Takeda N, Nishiike S, Kitahara T, Kubo T, Ogino H, Koizuka I (1997) Clinical features and utricular dysfunction in patients with benign paroxysmal positional vertigo. *Nihon Jibiinkoka Gakkai Kaiho* 100:449–456. <https://doi.org/10.3950/jibiinkoka.100.449>
37. Manzari L (2008) Enlarged vestibular aqueduct (EVA) related with recurrent benign paroxysmal positional vertigo (BPPV). *Med Hypotheses* 70(1):61–65. <https://doi.org/10.1016/j.mehy.2007.04.032>
38. Phillips JS, Prinsley PR (2009) A unified hypothesis for vestibular dysfunction? *Otolaryngol Head Neck Surg* 140:477–479. <https://doi.org/10.1016/j.otohns.2008.12.028>
39. Jahn AF (2017) Benign positional vertigo and endolymphatic hydrops: what is the connection? *J Laryngol Otol* 131(8):658–660. <https://doi.org/10.1017/S002221511700130X>
40. Morita N, Cureoglu S, Nomiya S, Nomiya R, Joglekar SS, Harada T, Paparella MM (2009) Potential cause of positional vertigo in Ménière's disease. *Otol Neurotol* 30(7):956–960. <https://doi.org/10.1097/MAO.0b013e3181b24368>
41. Gacek RR (2009) Meniere's disease is a viral neuropathy. *ORL Otorhinolaryngol Relat Spec* 2:78–86. <https://doi.org/10.1159/000189783>
42. Bartels LJ, Danner CJ, Allen KP (2016) Office-based Meniere's disease management. *Oper Tech Otolaryngol* 27:225–234. <https://doi.org/10.1016/j.otot.2016.10.009>
43. Jeong SH (2019) Kim JS (2019) Impaired calcium metabolism in benign paroxysmal positional vertigo: a topical review. *J Neurol Phys Ther* 43:S37–S41. <https://doi.org/10.1097/NPT.00000000000000273>
44. Becker-Bense S, Wittmann C (2019) Dieterich M (2019) Balanced sex distribution in patients with Ménière's disease. *J Neurol* 78:89. <https://doi.org/10.1007/s00415-019-09301-4>
45. Gürkov R, Flatz W, Ertl-Wagner B, Krause E (2013) Endolymphatic hydrops in the horizontal semicircular canal: a morphologic correlate for canal paresis in Ménière's disease. *Laryngoscope* 123(2):503–506. <https://doi.org/10.1002/lary.23395>
46. Parnes LS, McClure JA (1992) Free-floating endolymph particles: new operative finding during posterior semicircular canal occlusion. *Laryngoscope* 102:1988–1992. <https://doi.org/10.1288/00005537-199209000-00006>
47. Brandt T, Steddin S (1993) Current view of the mechanism of benign paroxysmal positioning vertigo: cupulolithiasis or canalolithiasis? *J Vestib Res* 3:373–382

Journal of Neurology is a copyright of Springer, 2021. All Rights Reserved.